

Use of Intermittent Pneumatic Compression for Treatment of Upper Extremity Vascular Ulcers

David H. Pfizenmaier II, MD, DPM,* Steven J. Kavros, DPM,[†]
David A. Liedl, RR, RVT,[‡] and Leslie T. Cooper, MD,^{§,¶} Rochester, MN

Ischemic vascular ulcerations of the upper extremities are an uncommon and frequently painful condition most often associated with scleroderma and small vessel inflammatory diseases. Digital amputation has been advocated as primary therapy because of the poor outcome with medical care. Intermittent pneumatic compression (IPC) pump therapy can improve ulcer healing in lower extremity ischemic ulcerations; however, the value of this treatment in upper extremity ischemic ulcerations is not known. This observational pilot study consisted of a consecutive series of 26 patients with 27 upper extremity ischemic vascular ulcers seen at the Mayo Gonda Vascular Center from 1996 to 2003. Inclusion criteria were documented index of ulcer size and follow-up ulcer size and use of the IPC pump as adjunctive wound treatment. Twenty-six of 27 ulcers (96%) healed with the use of the IPC pump. Mean baseline ulcer size was 1.0 cm² (SD=0.3 cm²) and scleroderma was the underlying disease in 65% (17/26) of cases. Laser Doppler blood flow in the affected digit was 7 flux units (normal greater than 100). The mean ulcer duration before IPC treatment was 31 weeks. The average pump use was 5 hours per day. The mean time to wound healing was 25 weeks. Twenty-five of 26 patients reported an improvement in wound pain with pump use. Intensive IPC pump use is feasible and associated with a high rate of healing in upper extremity ischemic ulcers. A prospective, randomized, sham-controlled study of IPC is needed to determine whether IPC treatment improves wound healing compared to standard medical care.

Introduction

Upper extremity digital ulcerations due to ischemia occur as a complication of scleroderma, mixed-connexive tissue disease, and vasculitis (Table 1). Standard medical therapy—including protection with dressings or mitts, optimal wound hygiene, topical agents, systemic vasodilators, and occasionally surgical, chemical sympathectomy—is rarely effective. Based on the Mayo Clinic Gonda Vascular Center (GVC) experience, more than one half of these ulcers fail to heal with standard medical therapy. Digital amputation is mainly required for control of pain and infection

Angiology 56(4):417-423, 2005

from the Division of Vascular Medicine and Internal Medicine

Department of Orthopedic Surgery, the Vascular Ulcer and Wound Healing Center, and the Division of Cardiovascular Disease and Internal Medicine, Mayo Clinic, Rochester, MN

There were no external sources of support for this study.

Correspondence: Leslie T. Cooper, MD, Consultant, Division of Cardiovascular Medicine, Mayo Clinic, 500 Fifth Street SW, Rochester, MN 55905.

E-mail: cooper@mayoclinic.edu

© 2005 Wolters Kluwer Health | Lippincott Williams & Wilkins
0000-2688/05/5604-0417\$5.00

and has been advocated as the initial treatment of choice.¹

External intermittent pneumatic compression (IPC) in the form of Circulator Boot™ therapy has been used as adjunctive therapy for lower extremities ischemic ulceration, with improvement in symptoms, healing, and limb salvage.^{2,3} The Aircast Arterioflow™ IPC pump is a home-use device that has been shown to increase distal laser Doppler blood flow (LDF, Figure 1). Use of the Aircast Arterioflow™ IPC pump has been associated with improved wound healing and limb preservation in critical ischemia of the lower extremities.⁴ In order to improve wound healing and pain relief in upper extremity ischemic ulcers, the Aircast Arterioflow™ IPC pump was added to the regimen of standard medical therapy at this facility.

Methods

We reviewed the medical records of all patients with upper extremity ulcers seen at the Mayo Gonda Vascular Center from 1996 to 2003. Twenty-six patients met the predefined criteria for inclusion: (1) documented measurements of

index ulcer size, (2) decreased upper extremity LDF obtained at the initial visit, (3) start of IPC pump therapy after the initial visit, and (4) documented follow-up with use of pump and ulcer measurements (Figure 2).⁵

Laser Doppler blood flow (LDF) was obtained by using a Perimed laser Doppler (Periflux System 5000, Jarfalla, Sweden). LDF was obtained at ambient room temperature and after warming of the digits for 20 minutes in a 45°C incubator (hot box) to exclude vasospasm as a cause for low laser Doppler flux.

Patients were seen at the GVC in follow-up at 4–6-week intervals. During each patient visit, ulcers were measured and digital photographs taken to document wound size. Representative cases are illustrated in Figures 3 and 4. If patients presented with more than 1 ulcer, the largest ulcer was chosen as the index lesion. Descriptive statistical analysis consisted of means and standard deviations to describe distributions.

Results

The study population consisted of 26 patients with 27 ischemic upper extremity ulcerations.

Table 1. Etiologies of upper extremity vascular ulcers.

Autoimmune diseases (scleroderma, MCTD)
Autoimmune vasculitis
Arteriosclerosis obliterans
Diabetes mellitus
Thromboembolism
Thrombophilia
Trauma (hammer-hand, frostbite)
Neuropathy
Drugs (ergotamine, cocaine)
Thromboangiitis obliterans (Buerger's)
"Steal"—AV fistula for dialysis

MCTD = mixed-connective tissue disease.

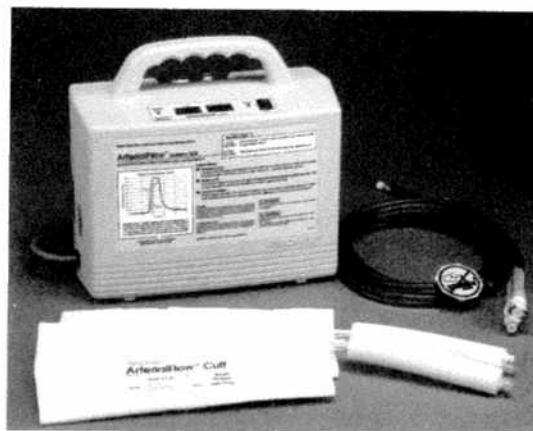

Figure 1. Aircast Arterioflow™ Intermittent Pneumatic Compression (IPC) Pump.

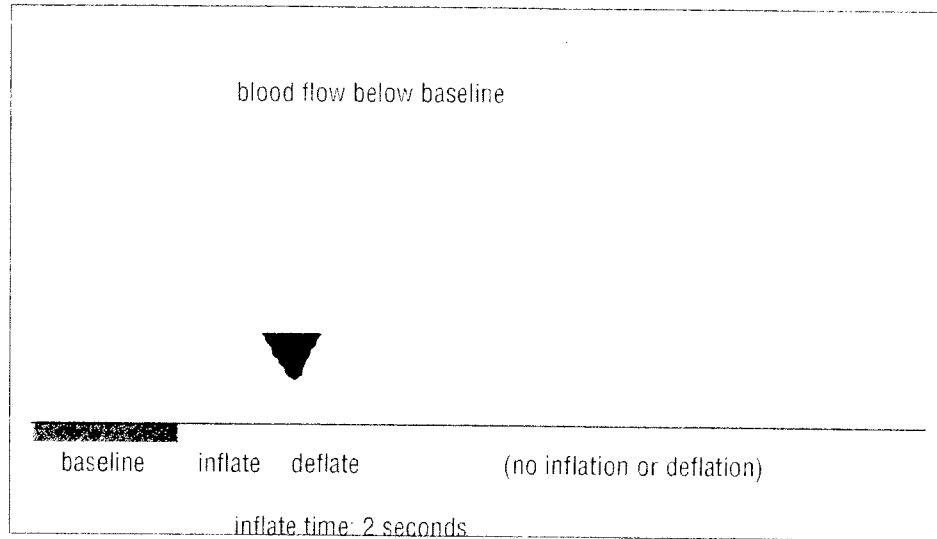


Figure 2. Digital laser Doppler flowmetry showing increased capillary blood flow with inflation and following deflation of the extremity cuff. The first peak above baseline (gray) is due to increased arterial flow from direct compression of the cuff. The second peak above baseline (also gray) is due to an increase in capillary flow resulting from decreased venous pressure in the extremity (“vortex” effect from pump-related venous emptying).

Table II. Demographics for 26 patients with 27 upper extremity digital ulcers.

Most Common Etiology	87% Autoimmune (65% Scleroderma)
Mean age at ulcer onset	52 years (SD = 11 years)
Gender	81% Female
Race	96% Caucasian
Diabetes	19%
Tobacco use	8% (current)/31% (previous)
Hypertension	50%

Eighty-one percent were female and 96% were Caucasian (Table II). The average age at ulcer onset was 53 years (SD = 11 years). Autoimmune disorders were present in 88% (23/26) of patients, with scleroderma representing 65% (17/26). Arteriosclerosis obliterans was involved in 12% (3/26) of patients. Mean baseline ulcer size was 1.9 cm² (SD = 0.3 cm²). All ulcers were chronic with a mean duration of 31 (SD = 37)

weeks. Mean baseline laser Doppler flowmetry values at room temperature were 7 flux units (normal >100) and mean postheat (45°C) values were 20 flux units (normal >200), which was consistent with the presence of fixed-occlusive arterial disease.

The mean daily duration of pump use was 3 (SD = 1.5) hours. As part of standard medical care, all patients received topical treatments and

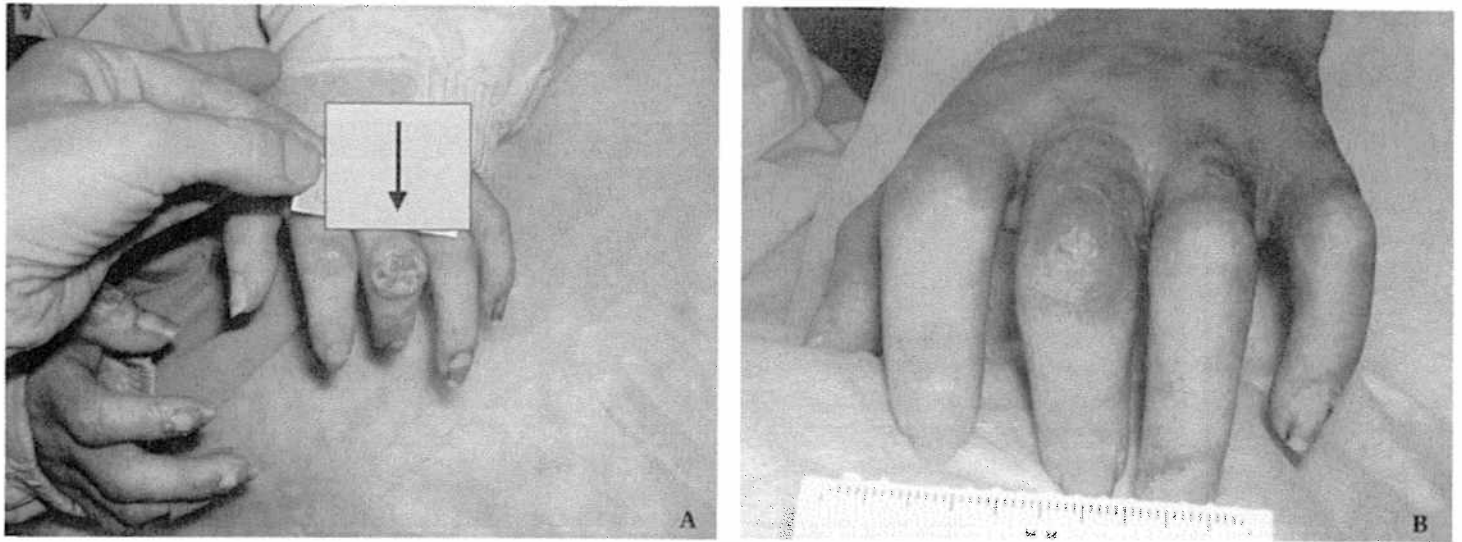


Figure 3. Scleroderma in a 48-year-old woman with multiple digital ulcerations. **A.** The largest ulcer (black arrow) was considered the index ulcer at a size of 1.7×1.4 cm. The ulcer had been present for 45 weeks and treated with standard therapies before use of the pump. **B.** Subsequently, the ulcer healed in 21 weeks.

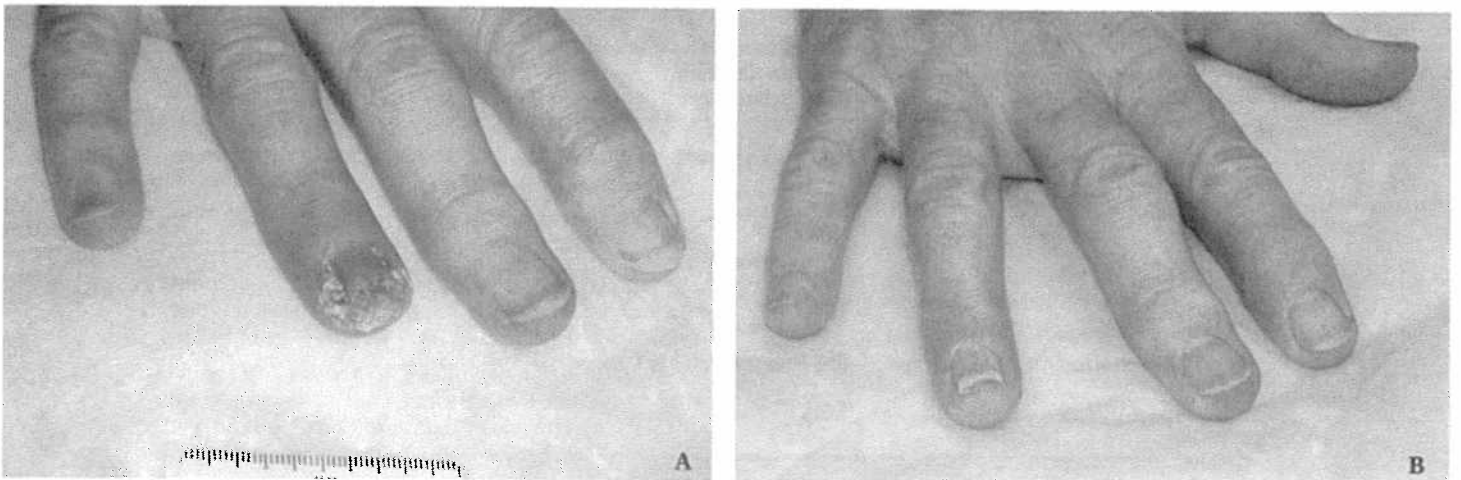


Figure 4. **A.** Mixed-connective tissue disease in a 61-year-old woman who developed a 1.5×1.3 cm ulcer of the right 4th finger after an episode of vasculitis. The ulcer had been present for 12 weeks after treatment of vasculitis with standard ulcer therapies. Four weeks before use of the pump, the patient underwent chemical sympathectomy of the affected extremity without benefit. **B.** Once pump therapy was initiated, the patient's pain improved and the ulcer subsequently healed in 8 weeks.

Table III. Summary of results in 26 patients with 27 upper extremity digital ulcers.

Healing of ulcers	96% (26/27)
Digits requiring amputation	4% (1/27)
Mean baseline ulcer size	1 cm ²
Mean baseline laser Doppler flow	7 (normal > 100)
Mean baseline laser Doppler flow postheat	20 (normal > 300)
Mean time to heal	25 weeks
Mean pump use	5 hours/day
Most common digits	2nd and 3rd fingers

drug therapies. Topical treatments included mostly cadexomer iodine gel alone (85%) or mixed with a hydrogel (63%). Oral drug therapies included vasodilating agents such as calcium-channel blockers (78%), alpha blockers (48%), and nitrates (22%). Antibiotics were used in 44%, and anti-platelet agents were used in 70%.

Twenty-six of 27 upper extremity ulcers (96%) healed after use of the IPC pump (see Table III). One digit required amputation. The mean time to wound healing was 25 (SD = 31) weeks, or 19 (SD = 11) weeks if 1 outlier (168 weeks) was removed. Two patients (8%) reported worsening pain at initiation of pump use that subsequently improved after several days of continued pump therapy. Overall, 25 of 26 patients reported improvement of pain after IPC therapy.

Discussion

This report is the first to suggest that IPC therapy is feasible and associated with a high rate of wound healing for upper extremity ischemic ulcerations. Montori *et al*⁶ previously showed that IPC pump therapy was associated with a 40% rate of lower extremity ulcers in 101 patients with critical limb ischemia (TcPO₂ < 20 mm Hg) who were at high risk of amputation. In that study, atherosclerotic occlusive disease was the predominant etiology. In contrast, autoimmune disorders, especially scleroderma, were the pre-

dominant etiologies of upper extremity vascular ulcers in the present study. In cases where surgical arterial bypass is not a therapeutic option, standard medical therapies for the treatment of vascular ulcers often fail. Limited data exist on other treatments for digital arterial occlusive disease and associated ulcers.⁷⁻⁹

The mechanism of benefit of IPC therapy is not known, but IPC therapy is associated with short-term elevation in digital blood flow (Figure 2). One hypothesis is that this increase in digital blood flow results from the sequence of cuff inflation from distal to proximal, decreasing venous pressure and generating a gradient (vortex effect) that increases arterial flow through the capillaries. Over time, this elevated blood flow contributes to healing of ischemic digital ulcers.

This observational study is meant to be "hypothesis-generating," rather than definitive, and indeed generates more questions than answers. Our study demonstrates the feasibility and tolerability of IPC treatment in the upper extremities. However, major design limitations that prevent definitive efficacy conclusions include the lack of a simultaneous control group and potential referral bias at our tertiary care center. It is possible that referring physicians sent their worst cases directly to amputation, and we failed to capture those events. Furthermore, the additive benefit of IPC therapy over state-of-the-art medical care cannot be measured without a randomized, sham-treated control group. However, if one compares our observed rate of amputation to similar cohorts from other published reports,

IPC therapy may be associated with a substantial treatment benefit.¹

Future studies of IPC therapy should be designed to answer several questions. The optimal duration of pump use per day is not known. The subjective reduction in pain observed with the use of the pump should be quantified with validated, standardized questionnaires. Functional assessment of upper extremities and quality of life instruments should be utilized. These questions could be answered by a prospective, randomized, sham-controlled study of IPC treatment of upper extremity ulcers.

REFERENCES

1. Gahhos F, Ariyan S, Frazier WH, et al: Management of sclerodermal finger ulcers. *J Hand Surg—American Volume* 9:320-327, 1984.
2. Dillon RS: Fifteen years of experience in treating 2,177 episodes of foot and leg lesions with the circulator boot. Results of treatments with the circulator boot. *Angiology* 48(suppl):S17-S34, 1997.
3. Vella A, Carlson LA, Blier B, et al: Circulator boot therapy alters the natural history of ischemic limb ulceration. *Vasc Med* 5:21-25, 2000.
4. Montori VM, Kavros SJ, Walsh E, et al: Intermittent compression pump for nonhealing wounds in patients with limb ischemia. *Int Angiol* 21:360-366, 2002.
5. Schabauer AMA, Rooke TW, Cutaneous laser Doppler flowmetry: Applications and findings. *Mayo Clin Proc* 69:564-574, 1994.
6. Janevski B: Arteries of the hand in patients with scleroderma. *Diagn Imaging Clin Med* 55:262-265, 1986.
7. Tomaino MM: Digital arterial occlusion in scleroderma: is there a role for digital arterial reconstruction? *J Hand Surg—British Volume* 25:611-613, 2000.
8. O'Brien BM, Kumar PA, Mellow CG, et al: Radical microarteriolytic treatment of vasospastic disorders of the hand, especially scleroderma. *J Hand Surg—British Volume* 17:447-452, 1992.
9. Milburn PB, Singer JZ, Milburn MA: Treatment of scleroderma skin ulcers with a hydrocolloid membrane. *J Am Acad Dermatol* 21:200-204, 1989.